

**EXERCISE FOR
SHOULDER ROM**
PAGE 2

**DIAGNOSTIC IMAGING
& CLINICAL FINDINGS**
PAGES 5

**ADHESIVE
CAPSULITIS & MORE**
PAGE 9

**SHOCKWAVE &
SHOULDER
LAMENESS**
PAGES 15

**INFRASPINATUS
CONTRACTURES**
PAGE 3

**DIAGNOSTIC IMAGING
& OCD**
PAGES 6 & 8

**SHOULDER
INSTABILITY &
OUTCOMES**
PAGE 13

**SHOCKWAVE &
BICEPS /
SUPRASPINATUS**
PAGES 16

FOURLEG NEWS



Hey gang! It's the shoulder issue!

So in this issue of FourLeg News, I wanted to do a literature search for NEW and relevant research articles pertaining to the shoulder! In doing so, I found 9 articles I thought were 'share-worthy'! Enjoy reading about them and taking in my comments about each article. If you're wanting any other topic researched and presented... just let me know! Cheers! Laurie

Apologies to those in the Southern Hemisphere for all the summer pictures... Summer in Canada is a big (short) deal!

Carr JG, Millis DL, Weng HY. Exercises in canine physical rehabilitation: range of motion of the forelimb during stair and ramp ascent. J Sm Anim Pract 54: 409-413, 2013.

Introduction:

ROM exercises in the forelimb of dogs has not been evaluated as thoroughly as the hindlimb in dogs. A previous study had found that incline walking on a treadmill (11% - angle of inclination 6.3°) had not significant effect on forelimb joint ROM when compared to walking on a level surface. Steeper inclines and stair ascent have not been tested.

Materials & Methods:

Eight female hound-type mixed breed dogs were used. The researchers evaluated forelimb joint ROM while jogging and during ascent up a set of standard stairs and during ascent up a ramp.

Both the stairs and the ramp had an angle of inclination of 35% (70% grade). Reflective markers were applied to the skin overlying the proximal spine of the scapula, greater tubercle of the humerus, lateral epicondyle of the humerus, ulnar carpal bone and the head of the 5th metacarpal bone, and digital, infrared cameras were arranged around the task area.

Each dog went was recorder performing 5 successful trials of stairs and ramp ascent, as well as flat surface trotting. (Trotting velocity was between 1.7 – 2.1 m/s)

Results:

Shoulder:

Greater flexion was seen with ascending the ramp as compared to ascending stairs. Flexion while ascending the ramp was significantly greater than trotting on flat. Shoulder peak extension was significantly greater ascending the ramp than trotting on flat, but trotting extension was greater than ascending stairs. And shoulder extension while ascending the ramp was greater than both ascending the stairs or trotting. Overall shoulder ROM was significantly greater while ascending the ramp, when compared to stairs or trotting on flat, however there was no significant difference in ROM between the stairs and flat surface trotting.

Elbow:

Both elbow flexion and extension were significantly greater with ramp and stair ascending as compared to trotting on flat. Ramp

*Class aptent taciti
sociosqu ad per
inceptos lobortis.*



*Praesent integer leo orci
aliquam, nibh a. Diam
nobis, erat natoque integer
fringilla viverra. Fermentu
pede fringilla urna semper,
pede quam scelerisque et
enim in commodo, dictum
a consequatur arcu. Praes
integer leo orci aliquam.
Feugiat dolor elit pede.*

ascending yielded greater ROM values over stair ascending.

Carpus:

Carpal flexion and extension values were greater for ascending both a ramp or stairs as compared to trotting. The ROM values for ascending the ramp were greater than those for ascending stairs.

Discussion:

Ascending stairs or ramps yields greater overall forelimb joint ROM compared to trotting on a flat surface. However, in order to achieve this effect, one must have a steep enough slope. One needs to bear in mind that these were normal, healthy dogs. Further studies are warranted to evaluate the usefulness of these activities in dogs with forelimb conditions.

Laurie's Thoughts:

You may choose stair or ramp ascent as part of your rehab program should you be wishing to provide active ROM exercises for your forelimb patient. This is pretty basic research, but it gets out there some of what we see and believe when working with our canine patients, and as such, is relevant base research.



Orellana-James, N. G., Ginja, M.M., Regueiro, M., Oliveira, P., Gama, A., Rodriguez-Altonaga, J.A., Gonzalo-Orden, J.M., Sub-acute and chronic MRI findings in bilateral canine fibrotic contracture of the infraspinatus muscle *Journal of Small Animal Practice*, vol. 54, pp. 428-431, 2013.

This is a case study of an individual dog, a GSP, showing a front end gait abnormality with no known history of trauma. This is typical of dogs with fibrotic contracture of the infraspinatus muscle as it is a condition more often diagnosed in working and sporting dogs, and likely occurs due to several microtraumas over time rather than a specific traumatic event.

The six year old female dog was presented for examination due to a recurring history of lameness in the front right limb (16 months ongoing) followed by lameness in the left front limb (3 months ongoing) which presented as an external rotation of the left distal forelimb, also typical of a sub-acute contracture.

On physical examination no pain or crepitus was found in the shoulders, but bilaterally she was unable to achieve full flexion on the glenohumeral joints during adduction. The right infraspinatus muscle was atrophied while the left was swollen. Other muscles showed no atrophy or swelling. No abnormalities were detected on radiographs.

MRI results on the right showed a reduction in the volume of the infraspinatus muscle and a central area of homogenous hypointense signal, surrounded by an area of heterogenous hypointense signal as a result of muscle degeneration and the replacement of that muscle with fibrous tissue.

Results on the left showed enlargement of the left infraspinatus, with a hyperintense circular signal in the muscle with a peripheral heterogeneous signal caused by oedema and haemorrhage.

Treatment in both cases was the same, a bilateral tenectomy of the insertion tendons of the infraspinatus muscles. A fasciotomy was also performed on the left infraspinatus and a drain inserted to prevent recurrence.

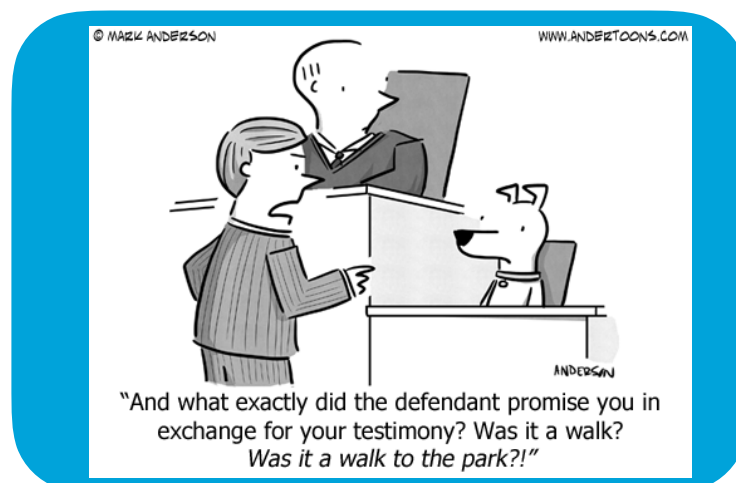
Three months post-op there was no recurring lameness, and the dog had normal range of motion in both shoulders.

When only one muscle at a particular shows abnormalities on the MRI, it is also characteristic of microtraumas rather than an external injury or single traumatic event. Repeat muscle strains cause localized damage that is repaired by satellite cell activation. However, as these cells become exhausted they lose their ability to repair and the muscle cells are replaced with adipose or fibrous tissue, as seen in the results of tissue analysis from samples taken from the dog during surgery.

This study showed different MRI results based on the type of contracture (sub-acute or chronic) and these corresponded to the slight difference in symptoms shown on each side. Based on these results the dog was diagnosed with a chronic contracture of the right infraspinatus and a sub-acute contracture of the left infraspinatus.

Laurie's Thoughts:

In started to look at all areas of tenderness in and around a joint, I believe I have picked up a number of infraspinatus pathologies before they became clinical enough to manifest as lameness or gait abnormalities. I now believe that they are slightly more common than we've been led to believe, and treating the mild cases can provide very rewarding results.



Maddox, T. W., May, C., Keeley, B.J., McConnell, J.F., *Comparison between shoulder computed tomography and clinical findings in 89 dogs presented for thoracic limb lameness* Vet Radiol Ultrasound, vol. 54, no. 4, pp. 358-364, 2013.

Objective

To document the prevalence and describe the type of CT lesions in the shoulders of individuals in a group of dogs exhibiting front limb lameness, and to investigate the significance of the presence of these lesions in relation to clinical findings.

Methods

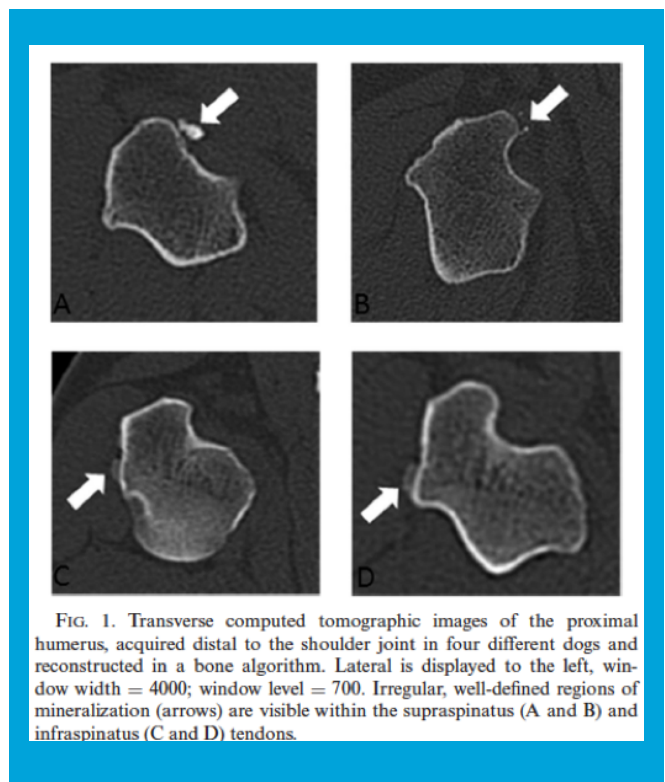
Records were obtained from two veterinary clinics comprising 89 pet dogs of varying breed that were presented for lameness in one or both front limbs that had undergone CT scans following clinical examination. Scans were done bilaterally on all dogs. Both the elbow and shoulder joints were scanned. CT interpretations were provided by either a board-certified or board-eligible veterinary radiologists who were aware of the clinical history of the dog in relation to each scan.

For the purposes of this study the author re-examined both the history reports and the scans of each dog. Lesions were identified as being either present or not present, but were not categorized by severity. The following independent variables were identified in the medical histories and recorded: weight, sex, age, breed, presence and degree of lameness, and pain or lameness localized to the shoulder.

Results

Overall analysis found that the prevalence of shoulder lesions was high, specifically peri-articular mineralization of the supraspinatus and biceps, in dogs with front limb lameness. There was no breed specific correlation, but the dogs most likely to have peri-articular mineralization lesions were medium to large breeds, with Labradors and Rottweilers most likely to have lesions detected on the supraspinatus and female dogs of any type were most likely to have supraspinatus lesion as well. However, despite the presence of these lesions in this analysis, results showed that peri-articular lesions were not significantly correlated with localized shoulder pain, rather of the 41 limbs with with shoulder mineralization 16 showed, no lameness at all. If lameness was present, then there was statistically significant occurrence of either another shoulder lesion or an elbow lesion. There was no significant correlation between shoulder mineralization and shoulder pain on it's own.

Osteochondrosis of the humeral head, however, did show a strong association with shoulder pain



and shoulder specific lameness, occurring most frequently in border collies involved in the study.

Laurie's Thoughts

Fascinating! Okay, so OCD causes pain and lameness, and supraspinatus mineralization did not. So with that being said, perhaps when you find a calcific lesion of supraspinatus on radiographs, you should spend a bit of extra time looking for any other cause of pain and lameness as well. (Treat the dog, not the x-ray, right?!)



Lande, R., Reese, S.L., Cuddy, L.C., Berry, C.R., Pozzi, A., *Prevalence of computed tomographic subchondral bone lesions in the scapulohumeral joint of 32 immature dog with thoracic limb lameness* Vet Radiol Ultrasound, vol. 55, n. 1, pp. 23-28, 2014.

Objective

To describe the subchondral bone lesions found in the scapulohumeral joints of a sample of immature dogs displaying front limb lameness. Specifically the prevalence of occurrence of the lesions, the location and size of lesions, and other CT abnormalities concurrent to the lesions; and to determine the presence or absence of subchondral bone lesions in relation to osteochondrosis of the caudal humeral head.

Methods

A sample size of 32 dogs (64 scapulohumeral joints) with a mean age of 10.7 months and including 17 different breeds was selected from veterinary records at the University of Florida. Dogs included were under 2 years of age and had no fractures or aggressive osseous lesions. All dogs in the sample had had a noncontrast CT scan performed on the scapulohumeral joints.

A board-certified veterinary radiologist conducted a blind review of each CT scan and recorded the following: the location, size, and shape of subchondral bone defects, the location and severity of subchondral bone sclerosis, osteophytes, and enthesophytes; and the severity of scapulohumeral joint effusion. The location size and shape of any other osseous or soft tissue lesions were also recorded.

Results

Of the 64 joints, 19 joints belonging to 13 dogs had scapulohumeral CT lesions (30% of joints). The remaining joints were considered normal. 19 of the 32 dogs had no CT lesions at all. Of the 13 dogs with scapulohumeral CT lesions, 10 had subchondral bone lesions. 16 scapulohumeral joints had osteochondral lesions, 14 of which were located in the caudal humeral head, while two were found in the glenoid cavity, a location not previously reported in dogs, but in horses and swine.


The characteristics of the glenoid cavity osteochondral lesions were similar in appearance to osseous cyst-like lesions described in horses.

All subchondral bone lesions were surrounded by sclerosis, ranging in severity from mild to moderate. For 14 of the 19 joints with scapulohumeral lesions, arthroscopy reports were available, and arthroscopic findings corresponded to the CT lesions.

Radiographs were only available for five dogs. In one of these five dogs the radiographs failed to show the abnormalities detected by the CT study. The abnormality in question was the osteochondral lesion in the glenoid cavity, not previously described in dogs, and only detected by the more sensitive CT study.

Laurie's Thoughts

This study is interesting from a descriptive standpoint. It points out that radiographs may not be as sensitive as we'd like (but then again only 5 of these dogs had radiographs). From a clinical standpoint, I'd say, if it looks and acts like a shoulder OCD lesion, without good evidence of it being something else, then treat it as such.



"Raise your right paw and bark after me."

Wall, C.R., Cook, C.R., Cook, J.L., *Diagnostic sensitivity of radiography, ultrasonography, and magnetic resonance imaging for detecting shoulder osteochondrosis/osteochondritis dissecans in dogs.* Vet Radiol Ultrasound, vol. 56, no. 1, pp. 3-11, 2015.

Objective

Using arthroscopy as the reference standard, to determine the sensitivity of radiography, ultrasonography, and MRI in the diagnosis of osteochondrosis/osteochondritis dissecans (OC/OCD) in a group of dogs showing a clinical history of front limb lameness compatible with the presumptive diagnosis of OC/OCD.

Methods

Eighteen client owned dogs for a sample size of thirty-six shoulder joints were selected. Each dog received all four of the diagnostics, radiography, ultrasonography, MRI, and arthroscopy. Blinded to the diagnostic image findings, one of three board-certified veterinary surgeons recorded the clinical history and arthroscopy results of each dog. Blinded to the arthroscopy results and the clinical history one of two board-certified veterinary radiologists recorded the diagnostic imaging findings.



Using the results of the arthroscopy as the standard for diagnosis, the accuracy of the three diagnostic imaging modalities was determined by their ability to determine the presence and size of OC lesions, in situ flaps, and free fragments.

Results

36 shoulders were evaluated by arthroscopy, 28 were found to be affected by OC/OCD lesions, 18 had in situ flaps, and 5 had free fragments. Of the 36 shoulders, radiography identified OC/OCD lesions in 24 shoulders, ultrasonography diagnosed lesions in 28 shoulders, and MRI in 26 shoulders. All were considered statistically useful overall.

Radiography was found to be the least sensitive, however, so in a dog suspected of having OC/OCD it would be prudent to pursue other diagnostic imaging even if the radiographs appear clear.

Ultrasonography was the least useful diagnostic modality due to limitations of depth of penetration and acoustic shadowing caused by the glenoid and other muscle structures in the canine shoulder. False positives were more likely when ultrasonography was used, and in this study four of the 28 lesions detected by ultrasonography were false positives, which in the clinical setting could lead to unnecessary



invasive treatment.

MRI scored high in both sensitivity and specificity. There was one false negative and one false positive in the MRI findings.

The ability to use non-invasive diagnostic imaging to rule out the presence of a OC/OCD lesion should reduce the need for exploratory arthroscopy.

Laurie's Thoughts

I just wish that MRI's weren't so expensive! So the radiographs missed 4 / 28 cases. However with previous studies we know that if it looks like and acts like an OCD lesion, it quite likely is (and don't be fooled by mineralizations of the supraspinatus tendon). So if you think it is, treat it as such... that's the clinician in me! (Use the compression test in shoulder flexion to help your thought processing - not yet studied, but clinically useful I think!)



Carr BJ, Canapp SO, Canapp DA, Gamble LJ, Dycus DL. Adhesive capsulitis in eight dogs: Diagnosis and management. Front Vet Sci, Vol 3, Article 55, July 2016.

Introduction:

Adhesive capsulitis, also known as frozen shoulder, is a syndrome defined by loss of range of motion of the shoulder and may be the end-stage manifestation of several primary conditions.

Of human patients affected by adhesive capsulitis, 70% are female and about 20–30% will develop the condition in the opposite shoulder. Only 20–30% of patients will report a history of minor trauma to the shoulder, and it has been found to be more common in those with sedentary lifestyles. Regardless of the biological cause, adhesive capsulitis is defined as thickening and contracture of the joint capsule, which results in decreased intra-articular volume and capsular compliance so that glenohumeral motion is limited in all planes.

In humans, frozen shoulder has 4 stages:

Stage 1: Pain with active or passive movement and progressive loss of ROM. The joint displays diffuse hypervascular glenohumeral synovitis (most pronounced in the anteriorsuperior capsule).

Stage 2: The freezing stage - is characterized by chronic pain and progressive loss of range of motion. There is a diffuse synovitis of the capsule with hypertrophic, hypervascular synovitis with perivascular and subsynovial scar formation and capsular fibroplasia.

Stage 3: The frozen stage – is characterized by minimal pain and significant shoulder stiffness. There is loss of capsular volume, and a dense, hypercellular collagenous tissue and a thin synovial layer without significant hypertrophy or hypervascularity.

Stage 4: The thawing stage - is characterized by minimal pain and progressive improvement in range of motion, resulting in capsular remodeling. (There is little information in the literature as to what these joints look like arthroscopically or histologically, since patients rarely undergo such procedures at this stage).

Materials & Methods:

Medical records were reviewed of 8 dogs diagnosed with frozen shoulder. Inclusion criteria for patients were a diagnosis of frozen shoulder based on the presence of the following: history of unilateral thoracic limb lameness, severe restriction of shoulder extension (<110°) and flexion (>90°), and pain on manipulation of the shoulder.

All dogs had routine radiographs. MRI was offered to all and elected by 5 of the 8 patients. Ultrasound was offered to all and elected for by 6 of the 8 patients. All dogs underwent shoulder joint arthroscopy. Three dogs received adipose derived progenitor cells into the shoulder joint and PRP injection to any concurrently affected tendons.

Results

Population

Patients consisted of 3 mixed breed dogs; 3 Welsh Corgis, 1 German Shepherd, & 1 Beagle, aging from 3 to 12 years of age, and comprised of 5 castrated males and 3 spayed females. All animals presented with a history of chronic, unilateral forelimb lameness, and only 3 of the 8 had a history of previous trauma to the affected shoulder within the last 1 – 1.5 years.

Ortho Exam:

Lameness was graded a 3-6 out of 6. All dogs exhibited moderate to significant discomfort with shoulder extension and flexion and restricted ROM in the affected shoulder: extension was <110° and flexion was >90°.



Four patients were too painful to allow ROM or abduction of the shoulder. Pain and spasm on direct palpation of the supraspinatus and biceps tendons was noted in 2 dogs. Six dogs displayed severe muscle atrophy of the shoulder musculature of the affected limb, and mild atrophy was noted in two. Two patients had medial compartment elbow pain, one had limited elbow extension. One patient had a 'shortened' feel to the biceps tendon. In three patients, there was pain, spasm and an empty end feel during the biceps stretch test. Only one had soft tissue swelling and effusion of the affected shoulder.

All were diagnosed with stage 2 Adhesive Capsulitis.

Radiographic findings: 2 dogs were normal. Of the other dogs, there were the following variable findings: soft tissue swelling and periosteal reaction of the distal scapula and humerus; sclerosis within the insertion of the capsule, teres, infraspinatus, and supraspinatus; remodeling and sclerosis within the bicipital groove; Severe remodeling, sclerosis and collapse in the joint space; a large caudal glenoid fragment; Osteophytosis of the caudal humeral head with flattening of the glenoid cavity.

Diagnostic Ultrasound findings (of 6 dogs): All showed evidence of fibrous scar tissue. Variable findings included: Disruption of the supraspinatus fiber pattern (short irregular fibers at the insertion); Hyperechoic and hypoechoic areas with disorganized fibre patterns; Normal supraspinatus was also noted in 3 dogs; Impingement of the supraspinatus on the biceps tendon; Calcification within the bicipital groove, impinging on the biceps tendon and a periosteal reaction at the supraglenoid tubercle; Fiber disruption at biceps point of origin and periosteal reaction; Fibrous scar tissue / adhesions of Teres and Infraspinatus; Joint capsule was hyperechoic, disrupted and thickened; and Shoulder joint effusion with free floating fibrous tissue.

MRI findings (of 5 dogs): All showed evidence of muscle atrophy. Variable findings included: Moderate effusion and enhancement of the synovial lining (including the part that envelops the biceps tendon) was found in 4 dogs; Severe biceps tendinopathy and mild joint effusion in 1 dog; Severe damage to the supraspinatus tendon and medial glenohumeral ligament; Severe shoulder dysplasia with severe OA; Mild supraspinatus, infraspinatus and teres minor insertionopathy; and 2 dogs had enlargement of the axillary lymph node.

Arthroscopy findings (of 5 dogs): Variable findings included: Significant amount of scar tissue and adhesions; Synovial inflammation and disruption; Moderate to severe inflammation of the biceps tendon and moderate bulge of the supraspinatus (impacting biceps tendon); Mild to moderate fraying and disruption of subscapularis, medial glenohumeral ligament, and medial compartment / joint capsule; Cartilage erosion along the caudal humeral head and glenoid.

Cytology and Histopathology (of 4 dogs): Cytology results were consistent with mononuclear inflammation in 3 dogs, and chronic sterile histiocytic inflammation with low grade to moderate grade chronic hemorrhage in one dog. The shoulder synovium was tested in one dog and histopathology was consistent with marked lymphoplasmacytic synovitis with fibrosis.

Conservative Management:

NSAIDS were prescribed for 7 patients, and the other patient was prescribed codeine. Five dogs were prescribed gabapentin and four were prescribed methocarbamol. Three were prescribed Traumeel (homeopathic anti-inflammatory agent). All were directed to take glucosamine/chondroitin sulfate

joint supplement and omega-3 fatty acid supplement. Two were prescribed a course of prednisone, and 3 received an intra-articular corticosteroid injection.

Weekly rehab (7 participated) consisted of manual therapy (massage, stretching, PROM, joint mobilizations), therapeutic ultrasound / TENS (combo unit), Laser/LED therapy (5J/cm²), and Magnetic field therapy. Five dogs also elected to do UWT sessions but discontinued after 2 sessions due to worsening of lameness. One dog elected for an amputation after a trial of conservative management. Five dogs receive 3 sessions of extracorporeal shockwave therapy, and two noted a slight improvement in lameness.



Stem Cell Therapy was utilized in three patients, and two of them received PRP injection in the affected supraspinatus. At recheck the supraspinatus tendon appeared to have a more organized fiber pattern (and reduced impingement on the biceps tendon was noted), however shoulder joint and bicipital sheath effusion remained, and neither lameness nor diagnostic ultrasound findings had improved at the 8-week check. One patient had a repeat stem cell procedure to the supraspinatus, which did improve its fiber organization 8 weeks later, but significant other degenerative changes were noted elsewhere. Overall, no improvements were seen in spite of regenerative medicine therapy.

Follow up (at a mean of 20.5 months) was possible for 5 of the dogs. None were reported to have any improvement, none of the owners felt that any of the therapies or treatment attempts helped. However, two of the owners reported that their dogs appeared to be subjectively more comfortable immediately following rehabilitation therapy.

Discussion

It is unclear in these cases whether the adhesive diagnosis is primary or potentially secondary to a chronic, untreated shoulder pathology. In the authors' opinion, just as in humans, adhesive capsulitis may be the end-stage manifestation of several primary conditions, it seems possible that regardless of the etiology of the primary shoulder pathology, chronic, untreated shoulder pathology could lead to adhesive capsulitis.

One recent human study found that 62% of human patients with idiopathic adhesive capsulitis were found to have concurrent supraspinatus lesions, and other studies have reported signs of supraspinatus, infraspinatus, and teres minor lesions as well. As such there could be a correlation with tendon lesions and frozen shoulder.

Therapy for human frozen shoulders is not very successful either. Corticosteroid injections may help with pain. Intensive manual physical therapy sessions can worsen patients. And for the most part, the condition is self-limiting and resolves over time. Physical therapies appear to be most helpful in the later stages of the condition.

In this case series, response to treatment was not similar to humans, and the condition did not resolve in any of the patients, despite the diagnostic appearance of the condition. Surgical treatments may need to be trialed and evaluated in the future.

Laurie's Thoughts

This is an interesting study, although disappointing that conservative therapies were found to be ineffectual! I would suggest in such cases, that maintenance therapies targeting pain management be considered. I'd not worry about trying to gain ROM or be aggressive with manual therapies, but I would use modalities and graded manual therapies that could help with pain management in these cases as a means of delivering some degree of comfort. I believe this would be justified, especially in light of the fact that there were reports of slight improvement with shockwave and some subjective comfort from rehab therapy. But it would appear from this study that canine adhesive capsulitis may not be 'fixable'.

Franklin SP, Devitt CM, Ogawa J, Ridge P, Cook JL. Outcomes associated with treatments of medial, lateral, and multidirectional shoulder instability in dogs. *Vet Surg* 42: 361-364, 2013.

This study sought to compare factors, treatments and outcomes associated with shoulder instability in dogs. It was a multi-center, retrospective cohort study that looked at 130 cases of shoulder instability.

Materials & Methods

Medical records of the cases at the authors' four hospitals were searched for dogs with diagnoses of shoulder instability associated lameness, with no concomitant or primary elbow, carpal or neurological pathology. Based on physical evaluation, radiographs and a subset of dogs that had diagnostic ultrasound, MRI or CT and were classified as having Medial Shoulder Instability (MSI), Lateral Shoulder Instability (LSI), or Multi-directional Instability (MDI).

Treatments were classified as surgical reconstruction, Radiofrequency-induced thermal capsulorrhaphy (RITC) or non-surgical. Outcomes for dogs with > 1 year of follow up were included and assessed for function and complications, and those that were not assessed at 1-year post diagnosis were called in order to acquire follow up information.

NOTE: Non-surgical, conservative management was not standardized and could include any combination of rest, nonsteroidal anti-inflammatory medication, intraarticular hyaluronic acid and/or steroid administration, use of hobbles, physical rehabilitation, and other nonsurgical treatments.

Results

130 dogs were identified: 43 males, 37 castrated males, 21 females, and 29 spayed females. Ages ranged from 1 to 13 years, and body weight was anywhere from 2.5 kg to 59 kg. 48% were affected in the left shoulder and 48% in the right, and 4% had bilateral shoulder injuries. Overall 41% were managed without surgical interventions (7% with RITC and 52% with reconstruction). MSI was the most common form of instability with 78% of dogs being affected. 8% had LSI and 15% had MDI.

MSI cases:

Of 101 cases, forty-eight dogs (48%) were prescribed nonsurgical management, 9 (9%) were treated with RITC, and 44 (44%) had surgical reconstruction. Of those treated surgically with RITC or reconstruction, 19 (36%) were initially treated nonsurgically for variable amounts of time, but were ultimately treated with surgery when outcome was considered unacceptable with nonsurgical management. Follow up (>1year) was available for 62/101 dogs (61%). Success was obtained in 9 (69%) dogs with nonsurgical management, 4 (80%) treated with RITC, and 38 (86%; 44 dogs were treated with 1 having surgical treatment bilaterally) dogs in which reconstruction was performed.

Complications occurred in 13% (appx. half being minor and half being major) of the dogs, and all occurred in association with surgical treatment rather than non-surgical management.

Surgical reconstruction had more favourable outcomes than non-surgical, and a non-significantly more favourable outcome over RITC. RITC was associated with a non-significantly more favourable outcome over non-surgical outcomes.

LSI cases:

LSI was diagnosed in 10 dogs, with 5 dogs being affected bilaterally. Only 7 dogs could be found for follow up. 5 had surgical reconstruction and 2 had conservative management. 1 of the non-surgical dogs went on to have surgery. Comparisons really could not be made.

MDI cases:

Nineteen dogs (21 shoulders) were diagnosed with MDI. Three (16%) dogs were managed without surgery and 16 (84%) had surgical reconstruction. Three (19%) of these had unacceptable results with nonsurgical management before having surgery. All were available for follow up > 1 year. Success was achieved in 2 (66%) of 3 dogs in the nonsurgical treatment cohort and 15 (83%) of 18 shoulders treated with reconstruction.




Discussion

“Our results indicate that the likelihood of a dog with MSI regaining full or acceptable function is significantly greater when treated with surgical reconstruction than when treated nonsurgically. Further, it appears qualitatively that a larger percentage of dogs with successful outcomes were considered to have full function, rather than just acceptable function, in the reconstruction group when compared with the nonsurgical management group.”

Although these data suggest that surgical reconstruction is superior to nonsurgical management for cases of MSI and MDI, the authors do not conclude that these data are sufficient to justify surgical treatment in all dogs with MSI or MDI.

Laurie's Thoughts

So, firstly, you may have already picked up on it on your own, but I think it's shoddy to compare non-uniform, non-described, potentially sub-standard quality of non-surgical care to standardized surgical procedures (i.e. surgery or RITC). My next concern is that it is evident that surgeons are presenting this paper, as no rehab professional would accept such an unfair comparison nor would they be content with 'conservative' management being described as anything from rest and NSAIDS to a comprehensive rehab regimen. So, quite frankly, shame on the authors for pushing this paper through as is and making broad sweeping statements such as, "Surgical reconstruction for treatment of MSI and MDI appears to produce a higher likelihood of achieving successful outcomes than nonsurgical management". On a personal note, I have NEVER had any of my MSI dog go for surgery. Even the worst case I've ever seen (a standard poodle with 90+° of abduction) did not need to have surgery of any kind and went back to sporting activities. This paper actually makes me quite mad! It highlights the importance of reading a paper in it's entirety, and not just relying on the abstract! Shame... Shame... Shame...



Becker W, Kowaleski MP, McCarthy RJ, Blake CA. Extracorporeal shockwave therapy for shoulder lameness in dogs. J Am Anim Hosp Assoc 51: 15-19, 2015.

This was a retrospective study of dogs that had received shockwave therapy for shoulder lameness at Cummings School of Veterinary Medicine at Tufts University. Dogs included in the study were those that had failed conservative management (rest, NSAIDS and nutraceuticals), and had lameness attributable to instability, calcifying and inflammatory injuries of the shoulder.

Records of 15 dogs that met the criteria were identified. Diagnosis was based on a combination of physical exam, radiography, ultrasonography, and/or arthroscopy of the shoulder. Five had biceps tendinopathy, four had medial shoulder instability, three had supraspinatus tendinopathy, one had both supraspinatus and a biceps tendinopathy, and one with synovial osteochondroma.

Nine dogs were physically evaluated 3-4 weeks after their last shockwave treatment and lameness was improved in 6 and normal in the remaining 3.

Eleven clients were available for telephone interviews (4 months – 61 months following intervention). Seven out of 11 dogs (64%) were considered by their owners to be either better or normal. Three dogs were considered to have the same degree of lameness as pretreatment.

ESWT details:

A focused electrohydraulic extracorporeal shockwave unit was utilized (Versatron 4 Paws – Pulse Vet Technologies). Three sessions in total were provided with 3 – 4 week intervals. ESWT electrode settings were based on recommendations from the manufacturer. The activity of the dogs was limited to short walks on a hand-held leash after the first treatment until evaluation 3–4 wk after the final treatment (i.e., 12–16 wk total). Analysis of the data revealed the mean number of impulses/treatment was 1103 +/- 340 (range, 750–1500) and the mean energy level of the impulse delivered was 0.24 +/- 0.03 mJ/mm² (range, 0.21–0.26 mJ/mm²).

Laurie's Thoughts:

Great! We know that shockwave can be of value. Clinically, we know that great rehab is more than just one treatment modality and should also include other therapies to provide a comprehensive therapeutic plan.

Leeman JJ, Shaw KK, Mison MB, Perry JA, Carr A, Shultz R. Extracorporeal shockwave therapy and therapeutic exercise for supraspinatus and biceps tendinopathies in 29 dogs. Vet Rec 179 (15):385, 2016.

Another retrospective study that looked at dogs with lameness attributable to biceps and supraspinatus tendinopathies, that were treated with extracorporeal shockwave. To be included in the study dogs were physically evaluated and diagnostic imaging interpreted by a radiologist, and medial shoulder instability and elbow disease were ruled out. 29 records were identified of dogs that met the criterion for inclusion in the study.

ESWT parameters:

A focused electrohydraulic shockwave system (VersaTron 4 Paws, Pulse Veterinary Technologies) was used. Treatment was either administered to the biceps tendon or the supraspinatus tendon and treated every 3 weeks for three treatments. Energy levels between E4 (0.14 mJ/mm²) and E6 (0.15 mJ/mm²) were used and an average of 989 pulses (750–1000) were administered per treatment.

Activity recommendations:

Therapeutic exercise recommendations were variable. Specific therapeutic exercises included eccentric strengthening such as down to stand, theraband exercises, wheelbarrowing, walking in water, and cavalettis. Core strengthening exercises included bird dog, begging, and challenged standing. Active and passive stretching were also recommended. For all dogs, it was recommended that no running, jumping or rough playing be allowed until permitted by the attending clinician. The recommended duration of leash walking was five minutes two to three times per day. This was increased by five minutes each week throughout the course of therapy as long as no lameness was noted and the patient’s normal length of walk was reached.

TABLE 3: Reported activity for 20 dogs receiving ESWT

Activity between ESWT treatments	Number of dogs (n=20)	Activity following ESWT treatments	Number of dogs (n=18)
No restrictions	1	No restrictions	2
Restricted activity	5	Restricted activity	5
TE	14	TE	11
Home	11	Home	9
1-3×/week	2	1-3×/week	2
3-5×/week	2	3-5×/week	3
More than 5×/week	6	More than 5×/week	4
Not reported	2	Not reported	0
Facility	1	Facility	2
1-3×/week	1	1-3×/week	1
3-5×/week	0	3-5×/week	0
More than 5×/week	0	More than 5×/week	0
Not reported	0	Not reported	0
Not reported	2	Not reported	0

ESWT, extracorporeal shockwave therapy; TE, therapeutic exercise

Additional therapies:

Some dogs received additional therapy consisting of hydrotherapy, therapeutic laser, and acupuncture.

Results

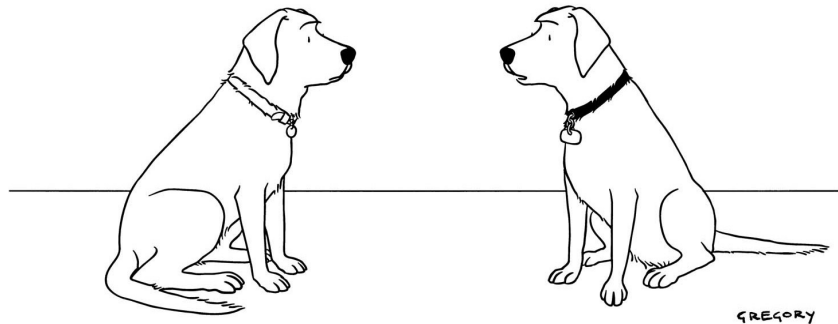
Of the 29 dogs included in the study, follow-up data (retrieved via mailed owner questionnaire and follow-up phone call) were available for 21 dogs. Reported therapeutic exercises prescribed or completed were variable. (see the table).

There was a significant association identified between severity of the tendon lesion diagnosed via MRI or US and outcome, with the best outcomes reported in dogs with moderate or severe lesions. Additionally, there was no statistically significant difference identified (P=0.92) in outcome when comparing dogs receiving ESWT and therapeutic exercise and those who received ESWT without therapeutic exercise.

As such, the authors suggest that ESWT, with or without therapeutic exercise, is a reasonable treatment option for dogs with any degree of shoulder tendinopathy.

Laurie’s thoughts:

Okay, again, shockwave shows to be beneficial. Yeah! But why even bring up therapeutic exercise in a study if it’s not being consistently prescribed, utilized or administered? Firstly, of the exercises described as ‘eccentric’ (which is known to stimulate tendon healing most effectually), only wheelbarrowing could actually be classified as eccentric. Secondly, why prescribe core exercises at all? Sure, everyone could use a better ‘core’, but those exercises do nothing to stimulate healing of a shoulder tendon. All in all, I wish this study hadn’t mentioned therapeutic exercise at all, because it’s conclusion (based on sub-standard utilization of therapeutic exercise) negates what we do in canine rehab, and know to be effective in human and laboratory animals both in research and clinical studies.



"I had my own blog for a while, but I decided to go back to just pointless, incessant barking."

Please feel free to leave this newsletter sitting out in your lunch room, or distribute it within your clinic or to your referring veterinarians. And if you have any ideas for a future Newsletter topic, just send me an e-mail!

Cheers! Laurie

Laurie Edge-Hughes, BScPT, MAnimSt (Animal Physio), CAFCI, CCRT



FourLegRehabInc

CANINE REHAB EDUCATIONAL RESOURCES

See what else is available to learn:

Visit www.fourleg.com

Drop me a line! Send me your questions!



Four Leg Rehab Inc

PO Box 1581,
Cochrane, AB T4C 1B5
Canada

Laurie@Fourleg.com